

## The Skeletal System

The skeletal framework of the body is composed of at least 206 bones and the associated tendons, ligaments, and cartilages. The skeletal system has a variety of important functions, including the support of soft tissues, blood cell production, mineral and lipid storage, and, through its relationships with the muscular system, the support and movement of the body as a whole. Skeletal system disorders can thus affect many other systems. The skeletal system is in turn influenced by the activities of other systems. For example, weakness or paralysis of skeletal muscles will lead to a weakening of the associated bones.

Although the bones you study in the lab may seem rigid and permanent structures, the living skeleton is dynamic and undergoing continual remodeling. The remodeling process involves bone deposition by osteoblasts and bone resorption by osteoclasts. As indicated in Figure A-16, the net result of the remodeling varies depending on:

1. **The age of the individual:** During development, bone deposition occurs faster than bone resorption, and the skeleton grows larger. At maturity, bone deposition and resorption are in balance; as the aging process continues, the rate of bone deposition declines and the bones become less dense. This gradual weakening, called *osteopenia*, begins at age 30–40 and may ultimately progress to *osteoporosis* (p. 54).

2. **The applied physical stresses:** Heavily stressed bones become thicker and stronger, and lightly stressed bones become thinner and weaker. Skeletal weakness can therefore result from muscular disorders, such as *myasthenia gravis* (p. 66) or the *muscular dystrophies* (p. 65), and conditions that affect CNS motor neurons, such as spinal cord injuries (p. 75), *demyelination disorders* (p. 72), or *multiple sclerosis* (pp. 72, 82).

3. **Circulating hormone levels:** Changing levels of growth hormone, androgens and estrogens, thyroid hormones, parathyroid hormone, and calcitonin increase or decrease the rate of mineral deposition in bone. As a result, many disorders of the endocrine system will have an impact on the skeletal system. For example:

- Conditions affecting the skin, liver, or kidneys can interfere with calcitriol production.
- Thyroid or parathyroid disorders can alter thyroid hormone, parathyroid hormone, or calcitonin levels.
- Pituitary gland disorders or liver disorders can affect GH or somatomedin production.
- Reproductive system disorders can alter circulating levels of androgens or estrogens.

Many of these conditions will be detailed in the section dealing with the endocrine system (pp. 87–94).

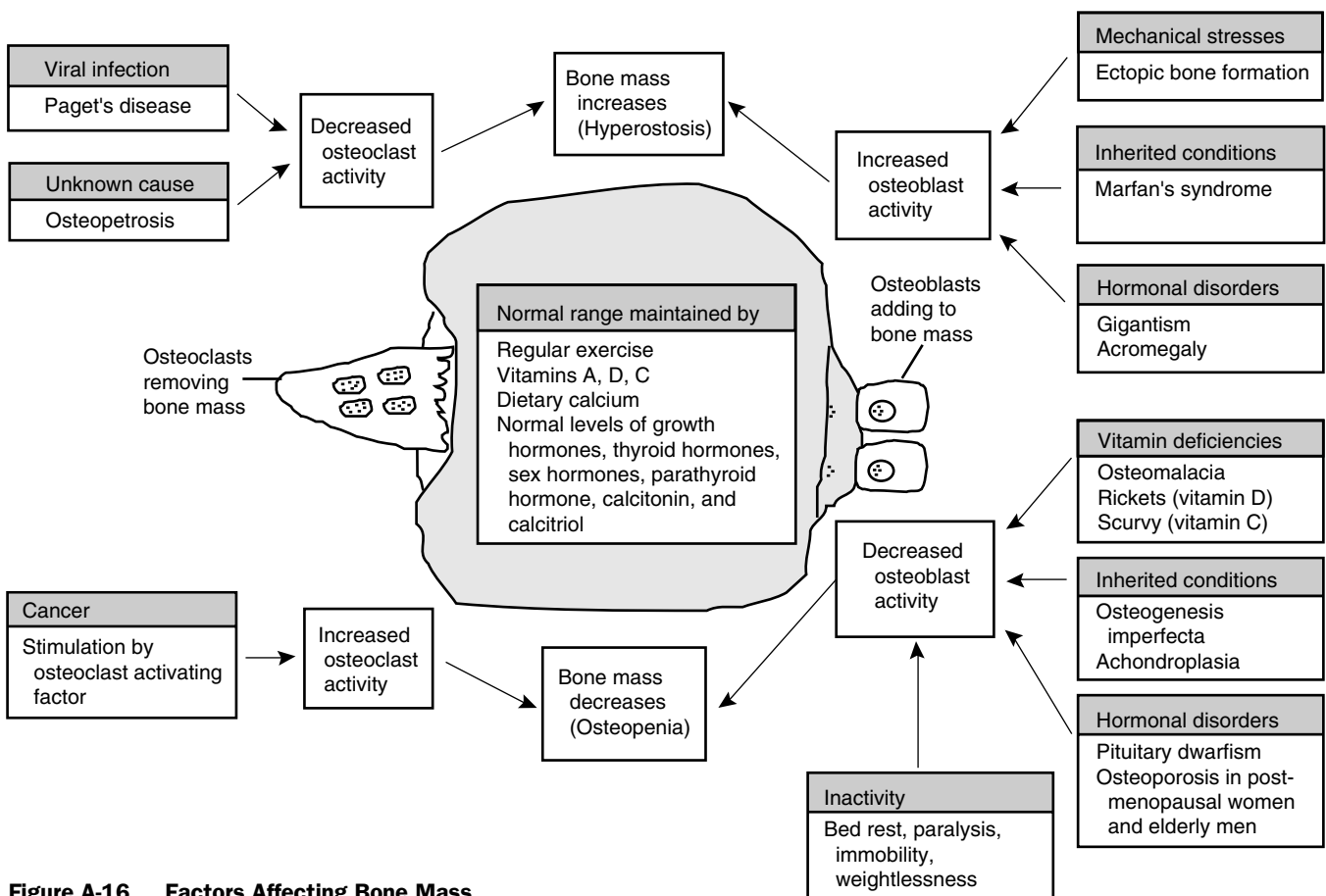


Figure A-16 Factors Affecting Bone Mass

4. **Rates of calcium and phosphate absorption and excretion:** For bone mass to remain constant, the rate of calcium and phosphate excretion, primarily at the kidneys, must be balanced by the rate of calcium and phosphate absorption at the digestive tract. Kidney failure or dietary calcium deficiencies or problems at the digestive tract affecting calcium and phosphate absorption will have a direct effect on the skeletal system.
5. **Genetic and environmental factors:** Genetic or environmental factors may affect the structure of bone or the remodeling process. There are a number of inherited abnormalities of skeletal development, such as *Marfan's syndrome* and *achondroplasia* (p. 53). When bone fails to form embryonically in certain areas, underlying tissues can be exposed and associated function can be altered. This occurs in a *cleft palate* (a condition in which the palatine processes of the maxillary bones do not fuse) and in *spina bifida* (p. 58). Environmental stresses can alter the shape and contours of developing bones. For example, some cultures use lashed boards to shape an infant's skull to a form considered fashionable. Environmental forces can also result in the formation of bone in unusual locations. These *heterotopic bones* may develop in a variety of connective tissues exposed to chronic friction, pressure, or mechanical stress. For example, cowboys in the nineteenth century sometimes developed heterotopic bones in the dermis of the thigh from friction with the saddle.

Figure A-17 diagrams the relationships between the major classes of skeletal disorders affecting bones and joints. Some of these conditions are the result of conditions that primarily affect the skeletal system (*osteosarcoma*, *osteomyelitis*) and others result from problems originating in other systems (*acromegaly*, *rickets*). These conditions affect the structure and function of the bones of the skeleton.

Traumatic injuries, such as fractures or dislocations, and infections also affect the cartilages, tendons, and ligaments associated with the bones involved. A somewhat different array of conditions affect the soft tissues of the bone marrow. Areas of red bone marrow contain the stem cells for red blood cells, white blood cells, and platelets. The bone marrow becomes abnormal in diseases of the blood that are characterized by blood cell overproduction (*polycythemia*, *leukemia*, pp. 98, 103) or underproduction (several *anemias*, pp. 99, 101).

## THE SYMPTOMS OF BONE AND JOINT DISORDERS

A common symptom of a skeletal system disorder is pain. Bone pain and joint pain are common symptoms associated with many bone disorders. As a result, the presence of pain does not provide much help in identifying a specific bone or joint

disorder. Chronic, aching bone or joint pain may be tolerated, and a person often will not seek medical assistance until more definitive symptoms appear. This may not occur until the condition is relatively advanced. For example, a symptom that may require immediate attention is a *pathologic fracture*. Pathologic fractures are the result of weakening of the skeleton by disease processes, such as *osteosarcoma* (a bone cancer). These fractures may be caused by physical stresses easily tolerated by normal bones.

## EXAMINATION OF THE SKELETAL SYSTEM

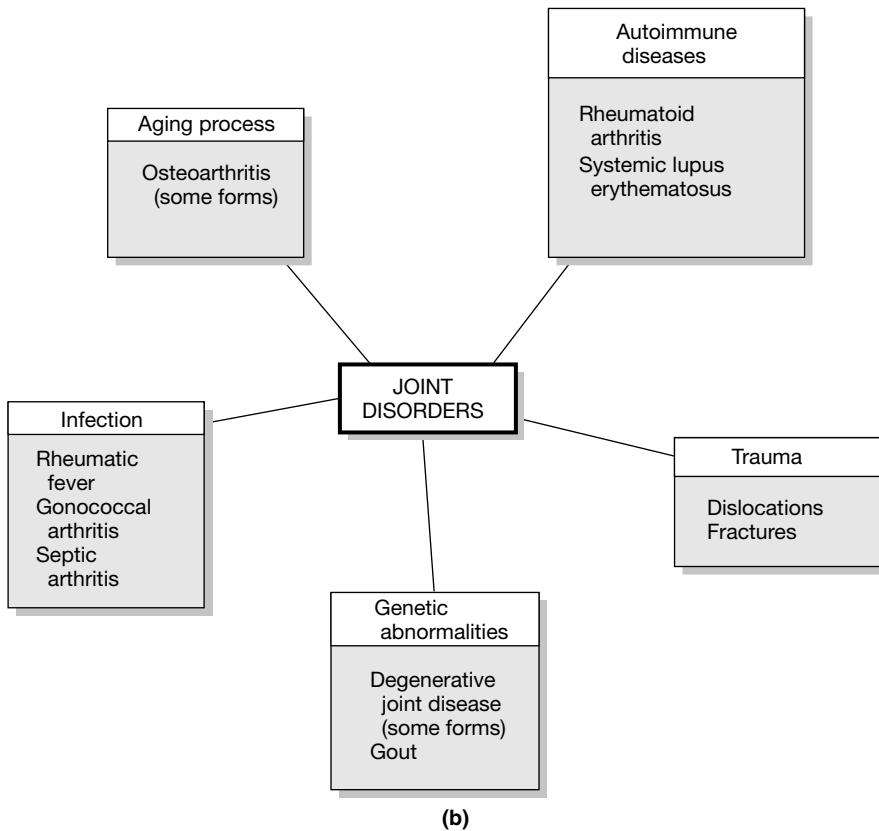
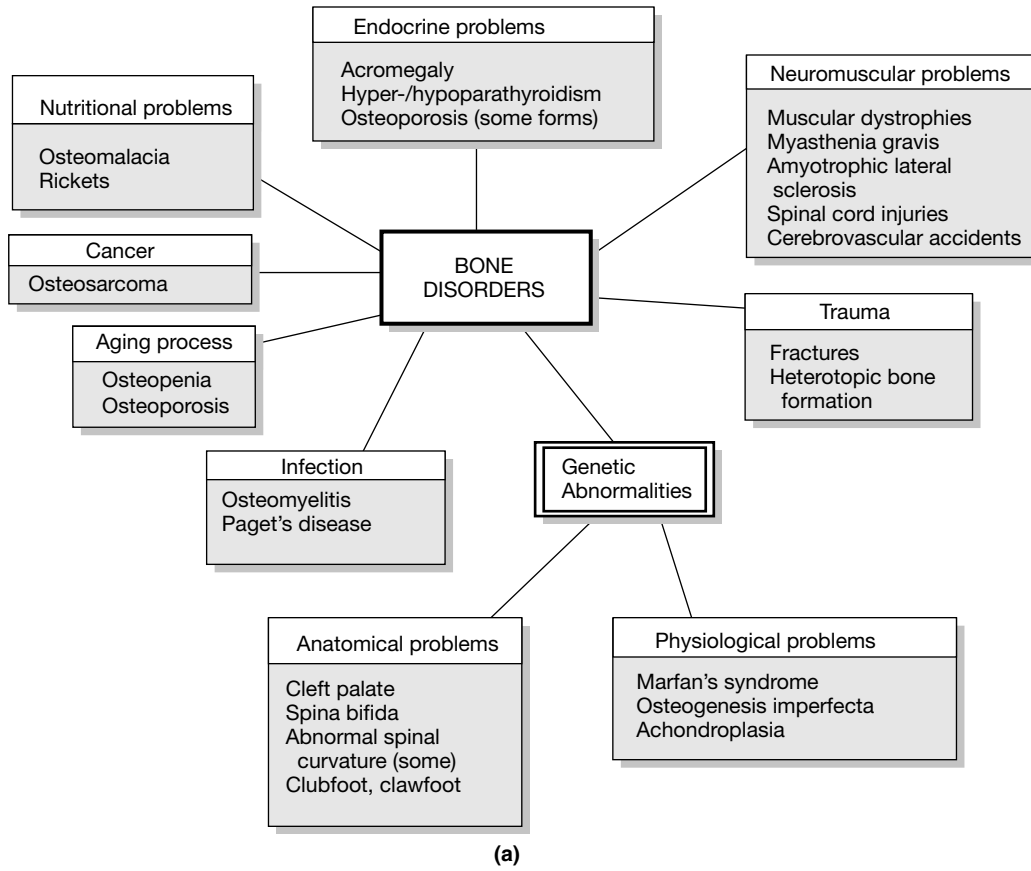
The bones of the skeleton cannot be seen without relatively sophisticated equipment. However, there are a number of physical signs that can assist in the diagnosis of a bone or joint disorder. Important factors noted in the physical examination include:

1. **Limitation of movement or stiffness:** Many joint disorders, such as the various forms of arthritis, will restrict movement or produce stiffness at one or more joints.
2. **The distribution of joint involvement and inflammation:** In a *monoarthritic* condition, only one joint is affected. In a *polyarthritic* condition, several joints are affected simultaneously.
3. **Sounds associated with joint movement:** *Bony crepitus* (KREP-i-tus) is a crackling or grating sound generated during movement of an abnormal joint. The sound may result from the movement and collision of bone fragments following an articular fracture or from friction and abrasion at an arthritic joint.
4. **The presence of abnormal bone deposits:** Thickened, raised areas of bone develop around fracture sites during the repair process. Abnormal bone deposits may also develop around the joints in the fingers. These deposits are called *nodules* or *nodes*. When palpated, nodules are solid and painless. Nodules, which can restrict movement, often form at the interphalangeal joints of the fingers in osteoarthritis.
5. **Abnormal posture:** Bone disorders that affect the spinal column can result in abnormal posture. This is most apparent when the condition alters the normal spinal curvature. Examples include *kyphosis*, *lordosis*, and *scoliosis* (p. 56). A condition involving an intervertebral joint, such as a herniated disc, will also produce abnormal posture and movement.

## Abnormalities in Skeletal Development

EAP p. 131

Several inherited conditions result in abnormal bone formation. Three examples are *osteogenesis imperfecta*, *Marfan's syndrome*, and *achondroplasia*.



**Figure A-17 An Overview of Disorders of the Skeletal System**  
 (a) Bone disorders. (b) Joint disorders.

**Osteogenesis imperfecta** (im-per-FEK-ta) is an inherited condition, appearing in 1 individual in about 20,000, that affects the organization of collagen fibers. Osteoblast function is impaired, growth is abnormal, and the bones are very fragile, leading to progressive skeletal deformation and repeated fractures. Fibroblast activity is also affected, and the ligaments and tendons are very “loose,” permitting excessive movement at the joints.

*Marfan’s syndrome* is also linked to defective connective tissue structure. Extremely long and slender limbs, the most obvious physical indication of this disorder, result from excessive cartilage formation at the epiphyseal plates (Figure A-18a). (Marfan’s syndrome is discussed further on p. 110.)

**Achondroplasia** (ā-kon-drō-PLĀ-sē-uh) is another condition resulting from abnormal epiphyseal activity. In this case the epiphyseal plates grow unusually slowly, and the individual develops short, stocky limbs. Although there are other skeletal abnormalities, the trunk is normal in size, and

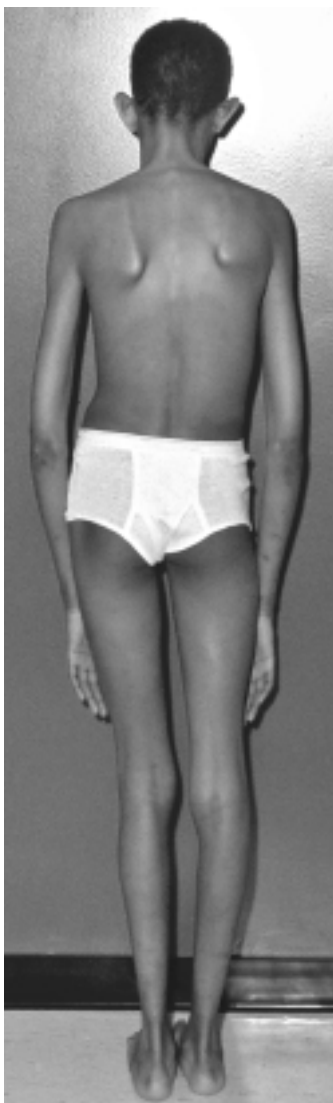sexual and mental development remain unaffected. An adult with achondroplasia is an *achondroplastic dwarf* (Figure A-18b).

In **osteomalacia** (os-tē-ō-ma-LĀ-shē-uh; *malakia*, softness), the size of the skeletal elements remains the same, but their mineral content decreases, softening the bones. In this condition the osteoblasts are working hard, but the matrix isn’t accumulating enough calcium salts. This can occur in adults or children whose diet contains inadequate levels of calcium or vitamin D<sub>3</sub>.

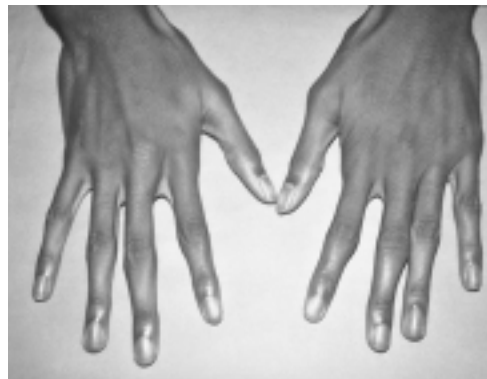### **Hyperostosis and Acromegaly**

EAP p. 133

The excessive formation of bone is termed **hyperostosis** (hī-per-os-TŌ-sis). In **osteopetrosis** (os-tē-ō-pe-TRŌ-sis; *petros*, stone) the total mass of the skeleton gradually increases because of a decrease in osteoclast activity. Remodeling stops, and the shapes of the bones gradually change. Osteopetrosis in children produces a variety of



(a)



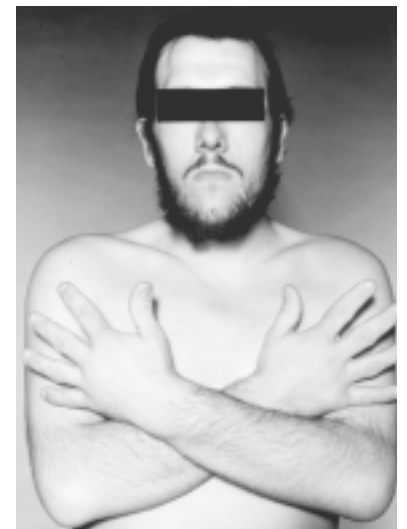(b)



(c)

**Figure A-18 Disorders of Bone Formation**

- (a) Marfan’s syndrome. (b) Achondroplasia. (c) Acromegaly.



skeletal deformities. The primary cause of this relatively rare condition is unknown.

In **acromegaly** (*akron*, extremity + *megale*, great), an excessive amount of growth hormone is released after puberty, when most of the epiphyseal plates have already closed. Cartilages and small bones respond to the hormone, however, resulting in abnormal growth at the hands, feet, lower jaw, skull, and clavicle. Figure A-18c shows a person with acromegaly.

6

## **R** Stimulation of Bone Growth and Repair

EAP p. 133

Despite the considerable capacity for bone repair, every fracture does not heal as expected. A *delayed union* is one that proceeds more slowly than anticipated. *Nonunion* may occur as a result of complicating infection, continued movement, or other factors preventing complete callus formation.

There are several techniques for inducing bone repair. Surgical bone grafting is the most common treatment for nonunion. This method immobilizes the bone fragments and provides a bony model for the repair process. Dead bone or bone fragments can be used; alternatively, living bone from another site, such as the iliac crest or part of a rib, can be inserted. As an alternative to bone grafting, surgeons can insert a shaped patch, made by mixing crushed bone and water. Bone transplants using bones from cadavers are performed, but in this case thorough sterilization is required to prevent the transmission of blood-borne diseases, such as AIDS. The calcium carbonate skeleton of tropical corals has been sterilized and used as another alternative.

Another approach involves the stimulation of osteoblast activity by strong electrical fields at the injury site. This procedure has been used to promote bone growth after fractures have refused to heal normally. Wires may be inserted into the skin, implanted in the adjacent bone, or wrapped around a cast. The overall success rate of about 80 percent is truly impressive.

One experimental method of inducing bone repair involves mixing bone marrow cells into a soft matrix of bone collagen and ceramic. This combination is used like a putty at the fracture site. Mesenchymal cells in the marrow divide, producing chondrocytes that create a cartilaginous patch that is later converted to bone by periosteal cells. A second experimental procedure uses a genetically engineered protein to stimulate the conversion of osteoprogenitor cells into active osteoblasts. Although results in animal experimentation have been promising, neither technique has yet been approved for human trials.

## Osteoporosis and Age-Related Skeletal Abnormalities

EAP p. 136


Our maximal bone density is reached in our early twenties and decreases as we age. Inadequate calcium in the diet of teenagers reduces peak density and increases the risk of osteoporosis. In **osteoporosis** (os-tē-ō-por-ō-sis; *porosus*, porous) there is a reduction in bone mass sufficient to compromise normal function. The distinction between the “normal” osteopenia of aging and the clinical condition of osteoporosis is therefore a matter of degree. Current estimates indicate that 29 percent of women between the ages of 45 and 79 can be considered osteoporotic. The increase in incidence after menopause has been linked to decreases in the production of estrogens (female sex hormones). The incidence of osteoporosis in men of the same age is estimated at 18 percent.

The excessive fragility of the bones frequently leads to breakage, and subsequent healing is impaired. Vertebrae may collapse, distorting the vertebral articulations and putting pressure on spinal nerves. Therapies that boost estrogen levels, dietary changes to elevate calcium levels in the blood, and exercise that stresses bones and stimulates osteoblast activity appear to slow but not completely prevent the development of osteoporosis.

Osteoporosis can also develop as a secondary effect of some cancers. Cancers of the bone marrow, breast, or other tissues release a chemical known as osteoclast-activating factor. This compound increases both the number and activity of osteoclasts and produces a severe osteoporosis.

Infectious diseases that affect the skeletal system become more common in older individuals. In part this reflects the higher incidence of fractures, combined with slower healing and reduction in immune defenses.

**Osteomyelitis** (os-tē-ō-mi-e-lī-tis; *myelos*, marrow) is a painful infection of a bone most often caused by bacteria. This condition, most common in people over 50 years of age, can lead to dangerous systemic infections. A virus appears to be responsible for **Paget’s disease**, also known as **osteitis deformans** (ost-ē-ī-tis de-FOR-man-z). This condition may affect up to 10 percent of the population over 70. Osteoclast activity accelerates, producing areas of acute osteoporosis, and osteoblasts produce abnormal matrix proteins. The result is a gradual deformation of the skeleton.

 **Individual Variation in the Skeletal System**

EAP p. 137

A comprehensive study of a human skeleton can reveal important information about the individual. For example, there are characteristic racial differences in portions of the skeleton, especially the skull and pelvis, and the development of various ridges and general bone mass can permit an estimation of muscular development and body weight. Details such as the condition of the teeth or the presence of healed fractures can provide information about the individual’s medical history. Two important details, sex and age, can be determined or closely estimated on the basis of measurements indicated in Tables A-15 and A-16. Table A-15 identifies characteristic differences between the skeletons of males and

**TABLE A-15 Sexual Differences in the Human Skeleton**

<i>Region/Feature</i>	<i>Male (as compared to female)</i>	<i>Female (as compared to male)</i>
<b>SKULL</b>		
General appearance	Heavier, rougher	Lighter, smoother
Forehead	Sloping	More vertical
Sinuses	Larger	Smaller
Cranium	About 10% larger (average)	About 10% smaller
Mandible	Larger, robust	Lighter, smaller
Teeth	Larger	Smaller
<b>PELVIS</b>		
General appearance	Narrow, robust, heavy, rough	Broader, lighter, smoother
Pelvic inlet	Heart-shaped	Oval to round
Iliac fossa	Relatively deep	Relatively shallow
Ilium	Extends farther above sacral articulation	More vertical; less extension above sacroiliac joint
Angle inferior to pubic symphysis	Under 90°	100° or more
Acetabulum	Directed laterally	Faces slightly anteriorly as well as laterally
Obturator foramen	Oval	Triangular
Ischial spine	Points medially	Points posteriorly
Sacrum	Long, narrow triangle with pronounced sacral curvature	Broad, short triangle with less curvature
Coccyx	Points anteriorly	Points inferiorly
<b>OTHER SKELETAL ELEMENTS</b>		
Bone weight	Heavier	Lighter
Bone markings	More prominent	Less prominent

**TABLE A-16 Age-Related Changes in the Skeleton**

<i>Region/Feature</i>	<i>Event(s)</i>	<i>Age (Years)</i>
<b>GENERAL SKELETON</b>		
Bony matrix	Reduction in mineral content	Values differ for males versus females between ages 45 and 65; similar reductions occur in both sexes after age 65.
Markings	Reduction in size, roughness	Gradual reduction with increasing age and decreasing muscular strength and mass.
<b>SKULL</b>		
Fontanels	Closure	Completed by age 2.
Metopic suture	Fusion	2–8
Occipital bone	Fusion of ossification centers	1–4
Styloid process	Fusion with temporal bone	12–16
Hyoid bone	Complete ossification and fusion	25–30
Teeth	Loss of “baby teeth”; appearance of secondary dentition; eruption of posterior molars	Detailed in Chapter 17 (digestive system).
Mandible	Loss of teeth; reduction in bone mass; change in angle at mandibular notch	Accelerates in later years (60+).
<b>VERTEBRAE</b>		
Curvature	Appearance of major curves	Shown in Figure A-20 and EAP Figure 6-16 ( <i>p. 000</i> ).
Intervertebral discs	Reduction in size, percentage contribution to height	Accelerates in later years (60+).
<b>LONG BONES</b>		
Epiphyseal plates	Fusion	Ranges vary, but general analysis permits determination of approximate age.
<b>PECTORAL AND PELVIC GIRDLES</b>		
Epiphyses	Fusion	Overlapping ranges somewhat narrower than the above, including 14–16, 16–18, 22–25 years.

females, but not every skeleton shows every feature in classic detail. Many differences, including markings on the skull, cranial capacity, and general skeletal features, reflect differences in average body size, muscle mass, and muscular strength. The general changes in the skeletal system that take place with age are summarized in Table A-16. Note how these changes begin at age 1 and continue throughout life. For example, fusion of the epiphyseal plates begins about age 3, and degenerative changes in the normal skeletal system, such as a reduction in mineral content in the bony matrix, typically do not begin until age 30–45.

An understanding of individual variation and of the normal timing of skeletal development is important in clinical diagnosis and treatment. Several professions focus on specific aspects of skeletal form and function.

### Septal Defects and Sinus Problems

EAP p. 143

Flushing the nasal epithelium with mucus produced in the paranasal sinuses often succeeds in removing a mild irritant. But a viral or bacterial infection produces an inflammation of the mucous membrane of the nasal cavity. As swelling occurs, the communicating passageways narrow. Drainage of mucus slows, congestion increases, and the victim experiences headaches and a feeling of pressure within the facial bones. This condition of sinus inflammation and congestion is called **sinusitis**. The maxillary sinuses are often involved. Because gravity does little to assist mucus drainage from these sinuses, the effectiveness of the flushing action is reduced, and pressure on the sinus walls typically increases.

Temporary sinus problems may accompany allergies or the exposure of the mucous epithelium to chemical irritants or invading microorganisms. Chronic sinusitis may occur as the result of a **deviated (nasal) septum**. In this condition the nasal septum has a bend in it, most often at the junction between the bony and cartilaginous regions. Septal deviation often blocks drainage of one or more sinuses, producing chronic cycles of infection and inflammation. A deviated septum can result from developmental abnormalities or injuries to the nose, and the condition can usually be corrected or improved by surgery.

### TMJ Syndrome

EAP p. 144

The temporomandibular joint permits a considerable degree of mandibular movement. The connective tissue sheath, or *capsule*, that surrounds the joint is relatively loose, and the opposing bone surfaces are separated by a fibrocartilage pad. In **TMJ syndrome**, the mandible is pulled

slightly out of alignment, usually by spasms in one of the jaw muscles. The individual experiences (1) facial pain that radiates around the ear on the affected side and (2) an inability to open the mouth fully.

TMJ syndrome is a repeating cycle of: muscle spasm → misalignment → pain → muscle spasm. It has been linked to unconscious behaviors, such as grinding of the teeth during sleep, and emotional stress. Treatment focuses on breaking the cycle of pain and muscle spasm and, when necessary, providing emotional support. The application of heat to the affected joint, coupled with the use of anti-inflammatory drugs or local anesthetics or both, may be helpful. If teeth grinding is suspected, special mouth guards may be worn at night.

### Kyphosis, Lordosis, Scoliosis

EAP p. 146

In **kyphosis** (ki-FŌ-sis), the normal thoracic curvature becomes exaggerated posteriorly, producing a “roundback” appearance (Figure A-19a). This can be caused by (1) osteoporosis or a compression fracture affecting the anterior portions of vertebral bodies, (2) chronic contractions in muscles that insert on the vertebrae, or (3) abnormal vertebral growth.

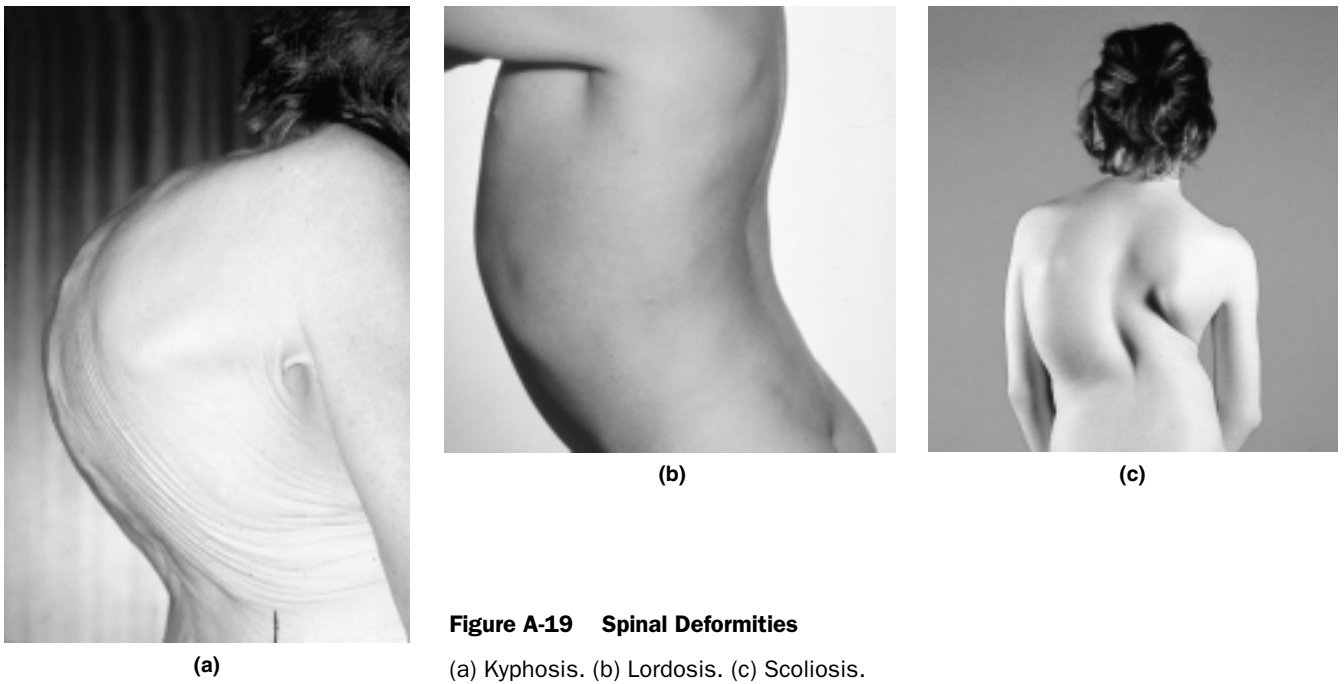In **lordosis** (lor-DŌ-sis), or “swayback,” both the abdomen and buttocks protrude abnormally. The cause is an anterior exaggeration of the lumbar curvature (Figure A-19b).

**Scoliosis** (skō-lē-Ō-sis) is an abnormal lateral curvature of the spine (Figure A-19c). This lateral deviation may occur in one or more of the movable vertebrae. Scoliosis is the most common distortion of the spinal curvature. Scoliosis may result from developmental problems, such as incomplete vertebral formation, or from muscular paralysis affecting one side of the back. In four out of five cases it is impossible to determine the structural or functional cause of the abnormal spinal curvature. Scoliosis usually appears in girls during adolescence, when periods of growth are most rapid. Treatment consists of a combination of exercises, braces, and sometimes surgical modifications of the affected vertebrae. Early detection greatly improves the chances for successful treatment.

### Problems with the Intervertebral Discs

EAP p. 146

An intervertebral disc compressed beyond its normal limits may become temporarily or permanently damaged. If the posterior ligaments are weakened, as often occurs with advancing age, the compressed inner, gelatinous core (the *nucleus pulposus*) may distort the outer, fibrocartilage layer (the *annulus fibrosus*), forcing it partway into the verte-



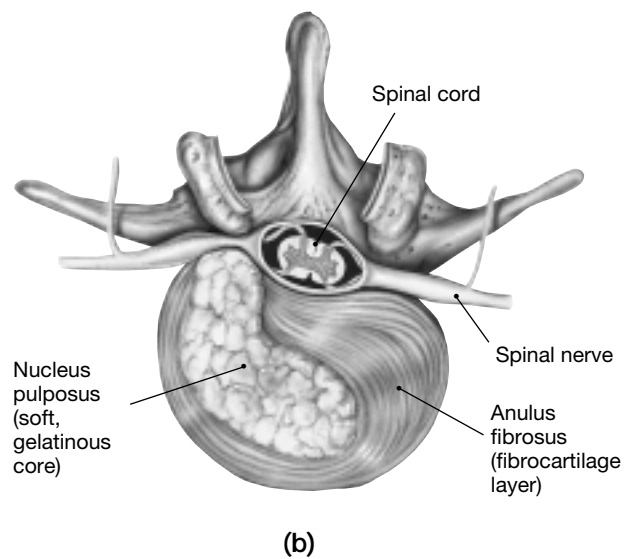
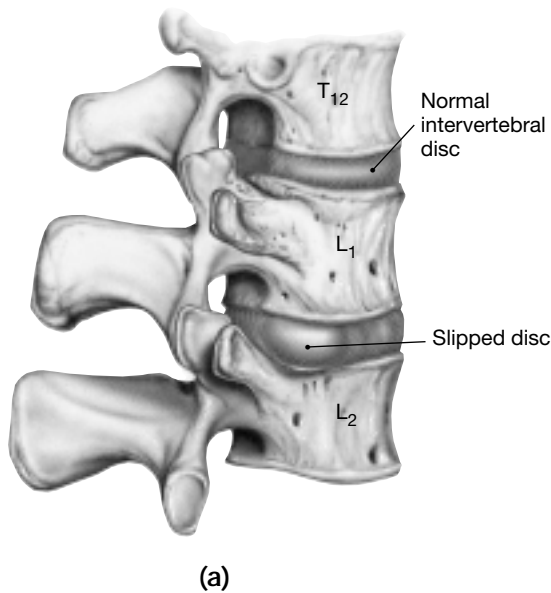
**Figure A-19 Spinal Deformities**

(a) Kyphosis. (b) Lordosis. (c) Scoliosis.

6

bral canal. This condition is often called a *slipped disc* (Figure A-20a), although the disc does not actually slip. The most common sites for disc problems are at C<sub>5</sub>–C<sub>6</sub>, L<sub>4</sub>–L<sub>5</sub>, and between L<sub>5</sub> and S<sub>1</sub>. A disc problem can occur at any age as the result of an accidental injury, such as a hard fall or a “whiplash” injury to the neck.

If the nucleus pulposus breaks through the annulus fibrosus, it often protrudes into the vertebral canal. This condition is called a **herniated disc** (Figure A-20b). When a disc herniates, sensory nerves are distorted, and the protruding mass can also compress the nerve roots passing through the adjacent intervertebral foramen. The



**FIGURE A-20 Damage to the Intervertebral Discs**

(a) Lateral view of the lumbar region of the spinal column, showing a distorted intervertebral disc (a “slipped” disc). (b) Sectional view through a herniated disc, showing release of the nucleus pulposus and its effect on the spinal cord and adjacent nerves.



result is severe back pain, an abnormal posture (abnormal vertebral flexion), abnormal sensory function, often a burning or tingling sensation from the lower back and lower limbs, and in some cases a partial loss of control over skeletal and pelvic muscles innervated by the compressed nerve fibers. Loss of bowel or bladder control is very rare (but a medical emergency if it occurs). The location of the injured disc can usually be determined by noting the distribution of abnormal sensations. For example, someone with a herniated disc at L<sub>4</sub>-L<sub>5</sub> will experience pain in the hip, groin, the posterior and lateral surfaces of the thigh, the lateral surface of the calf, and the top of the foot; a herniation at L<sub>5</sub>-S<sub>1</sub> produces pain in the buttocks, the posterior thigh, the posterior calf, and the sole of the foot.

Most lumbar disc problems can be successfully treated with some combination of rest, back braces, analgesic (painkilling) drugs, and physical therapy. Surgery to relieve the symptoms is required in only about 10 percent of cases involving lumbar disc herniation. The primary method of treatment involves removing the offending disc and, if necessary, fusing the vertebral bodies together to prevent relative movement. Accessing the disc requires that the laminae of the nearest vertebral arch be removed. For this reason the procedure is known as a *laminectomy* (la-mi-NEK-to-mē).

In rare cases in which the herniated portion of the disc does not extend far into the vertebral foramen, portions of the disc may be removed with a small tool that is guided to the site by radiological imaging. This procedure is faster and easier than is a laminectomy.



## Spina Bifida

EAP p. 147

**Spina bifida** (SPĭ-nuh BI-fi-duh) results when the vertebral laminae fail to unite during fetal development. The neural arch is incomplete, and the membranes that line the dorsal body cavity bulge outward. In mild cases, most often involving the sacral and lumbar regions, the condition may pass unnoticed. This condition, called *spina bifida occulta*, can be detected only through X-ray or other scanning procedures. Spina bifida occulta is very common, and it may affect 10 percent of the U.S. population. In some cases, the protective layers, or *meninges*, that surround the spinal cord may bulge through the open vertebral laminae. The result is a prominent fluid-filled sac, or *meningocele*, beneath the skin of the back.

The vertebral abnormalities in more severe forms of spina bifida are often associated with abnormal development of the spinal cord and associated nerves and muscles. Symptoms may range from mild problems with balance and movement to a general sensory and motor paralysis of the lower body.



## Problems with the Ankle and Foot

EAP p. 156

The ankle and foot are subjected to a variety of stresses during normal daily activities. In a *sprain*, a ligament is stretched to the point where some of the collagen fibers are torn. The ligament remains functional, and the structure of the joint is not affected. The most common cause of a **sprained ankle** is a forceful inversion of the foot that stretches the lateral ligament. An ice pack is usually required to reduce swelling, and with rest and support the ankle should heal in about three weeks.

In more serious incidents, the entire ligament may be torn apart, or the connection between the ligament and the malleolus may be so strong that the bone breaks before the ligament. In general, a broken bone heals more quickly and effectively than does a ruptured ligament. A dislocation may accompany such injuries.

In a **dancer's fracture**, the proximal portion of the fifth metatarsal is broken. This usually occurs while the body weight is being supported by the longitudinal arch. A sudden shift in weight from the medial portion of the arch to the lateral, less elastic border breaks the fifth metatarsal close to its distal articulation.

Individuals with abnormal arch development are more likely to suffer metatarsal injuries. Someone with flat feet loses or never develops the longitudinal arch. "Fallen arches" may develop as tendons and ligaments stretch and become less elastic. Obese individuals or those who must constantly stand or walk on the job are likely candidates. Children have very mobile articulations and elastic ligaments, so they often have flexible flat feet. Their feet look flat only while children are standing flat-footed, and the arch appears when they stand on their toes or sit down. This condition usually disappears as growth continues.

*Clawfeet* are also produced by muscular abnormalities. In this case the median longitudinal arch becomes exaggerated because the plantar flexors are overpowering the dorsiflexors. Muscle cramps or nerve paralysis may be responsible; the condition tends to develop in adults, and it gets progressively worse with age.

*Congenital talipes equinovarus* ("clubfoot") results from an inherited developmental abnormality that affects 2 in 1000 births. Boys are affected roughly twice as often as girls. One or both feet may be involved, and the condition may be mild, moderate, or severe. The underlying problem is abnormal muscle development that distorts growing bones and joints. Usually the tibia, ankle, and foot are affected, and the feet are turned medially and inverted. The longitudinal arch is exaggerated, and if both feet are involved, the soles face one another. Prompt treatment with casts or other supports in infancy helps alleviate the problem, and fewer than half of the cases

require surgery. Kristi Yamaguchi, Olympic Gold Medalist in figure skating, was born with this condition.



## Rheumatism, Arthritis, and Synovial Function EAP p. 159

**Rheumatism** (ROO-muh-tizm) is a general term that indicates pain and stiffness affecting the skeletal system, the muscular system, or both. There are several major forms of rheumatism. **Arthritis** (ar-THRI-tis) includes all the rheumatic diseases that affect synovial joints. Arthritis always involves damage to the articular cartilages, but the specific cause may vary. For example, arthritis can result from bacterial or viral infection, injury to the joint, metabolic problems, or autoimmune disorders.

Proper synovial function depends on healthy articular cartilages. When an articular cartilage has been damaged, the matrix begins to break down, and the exposed cartilage changes from a slick, smooth gliding surface to a rough feltwork of bristly collagen fibers. This feltwork drastically increases friction, damaging the cartilage further. Eventually the central area of the articular cartilage may completely disappear, exposing the underlying bone.

Fibroblasts are attracted to areas of friction, and they begin tying the opposing bones together with a network of collagen fibers. This network may later be converted to bone, locking the articulating elements into position. Such a bony fusion, called **ankylosis** (an-ke-LŌ-sis), eliminates the friction and pain, but as a result movement becomes impossible.

The diseases of arthritis are usually considered as either **degenerative** or **inflammatory** in nature. Degenerative diseases begin at the articular cartilages, and modification of the underlying bone and inflammation of the joint occur secondarily. Inflammatory diseases start with the inflammation of synovial tissues, and damage later spreads to the articular surfaces. We will consider a single example of each type.

**Osteoarthritis** (os-tē-ō-ar-THRĪ-tis), also known as **degenerative arthritis** or **degenerative joint disease** (DJD), usually affects older individuals. In the U.S. population, 25 percent of women and 15 percent of men over 60 years of age show signs of this disease. The condition seems to result from cumulative wear and tear on the joint surfaces. Some individuals, however, may have a genetic predisposition to develop osteoarthritis, for researchers have recently isolated a gene linked to the disease. This gene codes for an abnormal form of collagen that differs from the normal protein in only 1 of its 1000 amino acids.

**Rheumatoid arthritis** is an inflammatory condition that affects roughly 2.5 percent of the adult population. The cause is uncertain, although allergies, bacteria, viruses, and genetic

factors have all been proposed. The synovial membrane becomes swollen and inflamed, a condition known as **synovitis** (si-nō-VĪ-tis). The cartilaginous matrix begins to break down, and the process accelerates as dying cartilage cells release lysosomal enzymes.

Advanced stages of inflammatory and degenerative forms of arthritis produce an inflammation that spreads into the surrounding area. Ankylosis, common in the past when complete rest was routinely prescribed for arthritis patients, is rarely seen today. Regular exercise, physical therapy, and drugs that reduce inflammation, such as aspirin or ibuprofen, can slow the progress of the disease. Surgical procedures can realign or redesign the affected joint, and in extreme cases involving the hip, knee, elbow, or shoulder, the defective joint can be replaced by an artificial one. Joint replacement has the advantage of eliminating the pain and restoring full range of motion. Prosthetic (artificial) joints, such as those shown in Figure A-21, are weaker than natural ones and deteriorate in 10 or 15 years, but elderly people seldom stress them to their limits.



## Hip Fractures, Aging, and Professional Athletes EAP p. 165


Today there are two very different groups of people suffering hip fractures: (1) individuals over age 60, whose bones have been weakened by osteoporosis, and (2) young, healthy professional athletes, who subject their hips to extreme forces. When the injury is severe, the vascular supply to the joint is damaged. As a result, two problems gradually develop:

1. *Avascular necrosis*: The mineral deposits in the femur bones are turned over very rapidly, and osteocytes have high energy demands. A reduction in blood flow, to the femoral heads especially, first injures and then kills the osteocytes. When bone maintenance stops in the affected region, the matrix begins to break down. This process is called *avascular necrosis*.
2. *Degeneration of articular cartilages*: The chondrocytes in the articular cartilages absorb nutrients from the synovial fluid, which circulates around the joint cavity as the bones change position. A fracture of the femoral neck is usually followed by joint immobility and poor circulation to the synovial membrane. The combination results in a gradual deterioration of the articular cartilages of the femur and acetabulum.

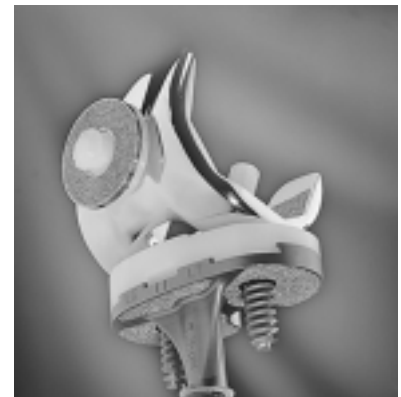In recent years, the frequency of hip fractures has increased dramatically among young, healthy professional athletes, the best-known example being Bo Jackson. At age 28 he was playing professional football with the LA Raiders and professional baseball



(a) Shoulder



(b) Hip



(c) Knee

**Figure A-21 Artificial Joints**

for the Kansas City Royals—and starring in both sports. He was also the centerpiece for successful advertising campaigns for sporting goods, using the “Bo knows” slogan. But on January 13, 1991, things changed dramatically when Bo was tackled near the sidelines in an NFL playoff game. The combination of pressure and twisting applied by the tackler and the tremendous power of Bo’s thigh muscles produced a fracture-dislocation of the hip. Roughly 15 percent of the inferior acetabular fossa was broken away. The femur was not broken, but it was dislocated. Although he experienced severe pain, the immediate damage to the femur and hip was sufficiently limited.

The initial optimism began to fade when it became apparent that the complications of the injury were more damaging than the injury itself. The dislocation tore blood vessels in the capsule and along the femoral neck, where the capsular fibers attach. The result was avascular necrosis and the degeneration of the articular cartilages at the hip.

After more than a year of rehabilitation, Bo Jackson had surgery to replace the damaged joint with an artificial hip. In this “total hip” procedure, the damaged portion of the femur was removed, and an artificial femoral head and neck is attached by a spike that extends into the marrow cavity of the shaft. Special cement may be used to anchor it in place and to attach a new articular surface to the acetabulum. After this procedure, Bo reentered professional baseball for a short time as a designated hitter and occasional first baseman, but his speed was diminished.

Joint replacement eliminates the pain and restores full range of motion. However, prosthetic (artificial) joints, such as those shown in Figure A-21, are weaker than natural ones. They are usually implanted in older people who seldom stress them to their limits. Current models deteriorate in 10 to 15 years, so young patients may need multiple replacements.

## CRITICAL-THINKING QUESTIONS

**2-1.** Diane, a 65-year-old woman, is brought into the emergency room by her daughter, Mary. Diane has had severe back pain since she fell accidentally yesterday. Her daughter insists it was a minor fall and is confused about the severity of the pain and tenderness over the thoracic spine. X-ray studies of the thoracic vertebrae reveal fractures of T<sub>10</sub>, T<sub>11</sub>, and T<sub>12</sub>. The X-rays also reveal a decreased bone density in all the vertebrae. Laboratory tests are within normal limits. The

physician diagnoses the fracture as a vertebral fracture most likely due to:

- a. osteomalacia
- b. osteomyelitis
- c. osteoporosis
- d. Paget’s disease

**2-2.** Beth, a dentist, has a patient complaining of a toothache on the lower right side of his mouth. Examination shows severe tooth decay in the first mandibular molar, with facial swelling along the mandibular angle. Beth suspects an infection and

takes an X-ray that shows a reduction in bone density around the root of the decayed tooth. What is the likely diagnosis?

- a. osteomalacia
- b. osteomyelitis
- c. fracture of the mandible
- d. tumor of the mandible

**2-3.** While studying a 2000-year-old campsite, an archeologist discovers several adult male and female skeletons. Chemical analysis of the bones of both sexes indicates that osteopenia had been occurring for several years before their deaths. The male skeletons all showed heavy thickenings and prominences in the bones of the upper limbs. The bones of the lower limbs were of normal size, and the markings indicated that only minimal muscle

stress had been applied during life. How old do you think these individuals were when they died, and what does the skeletal information tell you about the lifestyle of the males?

**2-4.** Lori suffers from a severe case of temporomandibular joint syndrome. What symptoms would you expect to observe as a result of this condition?

**2-5.** Two patients sustain hip fractures. In one case, a pin is inserted into the joint and the injury heals well. In another, the fracture fails to heal. Identify the types of fractures that are probably involved. Why did the second patient's fracture not heal, and what steps could be taken to restore normal function?